

Oroantral communication closure with Bichat adipose body: etiology, clinical and radiographic features

Fechamento de comunicação bucosinusal com bola de Bichat: considerações sobre os fatores etiológicos, sinais clínicos e radiográficos

Cerrado de comunicación buco-sinusal con bola de Bichat: consideraciones sobre los factores etiológicos, señales clínicas y radiográficas

Jefferson David Melo de **MATOS**¹
Andre Guimarães **RODRIGUES**²
Alessandra Dossi **PINTO**³
Marília Lasmar Gomes **PEREIRA**⁴
Lucas Augusto Pereira **SOUTO**⁴
Leonardo Jiro Nomura **NAKANO**¹
Guilherme da Rocha Scalzer **LOPES**¹
Marco Antonio **BOTTINO**⁵
Nathália de Carvalho **RAMOS**⁶
Danillo Costa **RODRIGUES**⁷
Valdir Cabral **ANDRADE**⁸

¹Post Graduate Student - Ph.D Program, Department of Dental Materials and Prosthodontics, São Paulo State University (Unesp), Institute of Science and Technology, São José dos Campos - SP, Brazil

²Graduated in Dentistry, Universidade Vila Velha, Vila Velha – ES, Brazil

³Graduated of Dentistry, Faculdade São Francisco de Assis ESFA, Santa Teresa – ES, Brazil

⁴Graduated in Dentistry, Universidade Estadual de Montes Claros UNIMONTES, Montes Claros – MG, Brazil

⁵Full Professor of Postgraduate Program in Restorative Dentistry, Department of Dental Materials and Prosthodontics, São Paulo State University (Unesp), Institute of Science and Technology, São José dos Campos - SP, Brazil

⁶Professor of Prosthodontics, Department of Dentistry, Universidade São Francisco USF, Bragança Paulista - SP, Brazil

⁷Professor of Maxillofacial Surgery, Department of Dentistry, Universidade Estadual de Montes Claros UNIMONTES, Montes Claros – MG, Brazil

⁸Adjunct Professor, Department of Dentistry and Maxillofacial Surgery, Universidade Federal de Juiz de Fora UFJF, Governador Valadares - MG, Brazil

Abstract

Objective: This study aims to clarify to the dentist about the possible etiological factors responsible for such complication, to identify its clinical and radiographic signs and to describe the surgical technique adopted in these cases. **Case Report:** For this purpose, the authors present the clinical case of a patient with post-exodontia oroantral fistula of the right permanent maxillary first molar. The proposed treatment was the closure of the fistula under local anesthesia using the Bichat adipose body, with advantages of being a simple procedure, easy to perform, that does not require specific material, minimal complications, low morbidity and can be performed in the own dental practice and with high success rates proven by several studies. **Discussion:** The oroantral fistula is a common pathological occurrence in the dental clinic, characterized by communication of the maxillary sinus with the oral cavity when the maxillary sinus is pneumatic or during dental extractions of upper posterior elements whose roots are closely related to the maxillary sinus. **Conclusion:** Communications should be treated immediately, if there are signs of inflammation it should be treated first, so that surgical correction can be performed later.

Descriptors: Oroantral Fistula; Fat Body; Surgery, Oral.

Resumo

Objetivo: Este estudo objetiva esclarecer ao cirurgião-dentista os possíveis fatores etiológicos responsáveis por essa complicação, identificando seus sinais clínicos e radiográficos e descrevendo a técnica cirúrgica adotada nesses casos. **Relato de Caso:** Para isso, os autores apresentam o caso clínico de um paciente com fístula buco-sinusal pós-exodôntica, do primeiro molar superior direito permanente. O tratamento proposto e executado foi o fechamento da fístula sob anestesia local, utilizando o corpo adiposo Bichat, com vantagens de ser um procedimento simples, de fácil execução, que não necessita de material específico, complicações mínimas, baixa morbidade e pode ser realizado no próprio consultório odontológico e com altas taxas de sucesso comprovadas por vários estudos. **Discussão:** A fístula buco-sinus é uma ocorrência patológica comum na clínica odontológica, caracterizada pela comunicação do seio maxilar com a cavidade oral quando o seio maxilar é pneumático ou durante extrações dentárias de elementos posteriores superiores cujas raízes estão intimamente relacionadas ao seio maxilar. **Conclusão:** As comunicações devem ser tratadas imediatamente, se houver sinais de inflamação, devem ser tratadas primeiro, para que posteriormente proceda à correção cirúrgica.

Descritores: Fístula Bucoantral; Corpo Adiposo; Cirurgia Bucal.

Resumen

Objetivo: Este estudio tiene por objetivo aclarar al cirujano dentista en cuanto a los posibles factores etiológicos responsables de tal complicación, identificar sus signos clínicos y radiográficos y describir la técnica quirúrgica adoptada frente a esos casos. **Reporte de Caso:** Para ello, los autores presentan el caso clínico de un paciente con fístula buco-sinusal post exodoncia, del primer molar superior derecho permanente. El tratamiento propuesto y ejecutado fue el cierre de la fístula bajo anestesia local utilizando el cuerpo adiposo de Bichat, teniendo por ventajas, ser un procedimiento simple, de fácil ejecución, que no necesita de material específico, complicaciones mínimas, baja morbilidad, pudiendo ser realizado en el propio consultorio odontológico y con altos índices de éxito comprobado por diversos estudios. **Discusión:** La Fístula Buco-Sinusal es una ocurrencia patológica común en la clínica odontológica, caracterizada por la comunicación del seno maxilar con la cavidad bucal cuando el seno maxilar se encuentra neumático, o durante extracciones dentales de elementos superiores posteriores cuyas raíces tienen íntima relación con el seno maxilar. **Conclusión:** Las comunicaciones deben ser tratadas de inmediato, si tiene signos de inflamación, ésta debe ser tratada primero, para que después proceda a la corrección quirúrgica.

Descriptorios: Fístula Oroantral; Cuerpo Adiposo; Cirugía Bucal.

INTRODUCTION

Oroantral fistula is a common pathological occurrence, where an opening or communication of the maxillary sinus with the oral cavity occurs, as a result of a loss of soft and hard tissue that normally separates the two compartments¹. These occurrences are often accidentally cause during dental

extractions of posterior maxillary elements whose roots are closely related to the maxillary sinus². These teeth are only 1 to 7 mm from the maxillary sinus. The main upper teeth involved are first permanent molars, followed by second and third molars³.

This fistula may occur due to an aggressive surgical technique, excess alveolar curettage after extraction and also to other less frequent etiological factors that cause a oroantral fistula, such as destruction of the sinus by periapical lesions and removal of cysts and/or palate or maxillary sinus tumors⁴.

The diagnosis of oroantral communication is made through detailed anamnesis, clinical and imaging examination, where the continuity of the radiopaque line that delimits the floor of the affected maxillary sinus can be observed, when compared with the adjacent side⁵. The most frequent complaints are related to the possible passage of food or fluids from the oral cavity to the sinus, nasal timbre, halitosis, runny nose, facial pain or frontal headache and the presence of unilateral nasal discharge⁶. For clinical diagnosis is recommended the visual inspection, alveolar palpation and Valsalva maneuver, which consists of forced nasal exhalation, which promotes alveolar air or pus through the fistula, depending on the state of the maxillary sinus⁷.

If the oroantral fistula is smaller than 2 mm in diameter, the most appropriate treatment is the stabilization of the clot and its preservation at the extraction site with the aid of a well-performed suture⁸. Usually this small fistula closes spontaneously, when the fistula is larger than 3 mm or when there is inflammation in the antrum or periodontal region, it is necessary the closure⁹.

Several methods for the closure of oroantral fistulas have been reported in the literature, such as oral and palatal flap sliding, use of bone grafts and material implants, inferior facial artery musculomucosal flap or myofascial temporal flap associated to the Bichat adipose body¹⁰. However, these procedures have not provided satisfactory results in all cases where such procedure was performed¹¹.

The buccal adipose body or Bichat's fat-pad consists of a main body resting on the maxillary periosteum and upper fibers of the buccinator muscle, which four processes extends: pterygopalatine, temporal, pterygoid and buccal¹². The adipose body is encapsulated in the cheek by a fascial envelope derived from the parotid-masseteric fascia¹³.

Several authors consider the Bichat adipose ball graft technique favorable for cases with severe damage to the palatal and/or buccal mucosa, and for preservation of vestibule depth and also for the high success rate obtained with the technique¹⁴. Due to their easy access and rich vascularization, it is considered a convenient and recommendable treatment for oroantral communications¹⁵.

This study aims to clarify to the dentist the possible etiological factors responsible for this complication, identify their clinical and radiographic

signs and describe the surgical technique adopted in these cases.

CLINICAL CASE

A 35-years-old male patient, melanodermic, presents the Oral and Maxillofacial Surgery and Traumatology Service of the Santa Casa de Misericórdia in Montes Claros, complaining of fluid passing from the oral cavity to the nasal cavity, in addition to halitosis and pain in the region. The patient reported that the communication appeared one week after upper right first molar extraction. Intraoral clinical examination showed the presence of a defect in the alveolar ridge in the attempt to close the fistula. Patient reported not being a smoker and not having any drug disorders or allergies, presented normal pulse, blood pressure and respiratory rate (Figure 1).

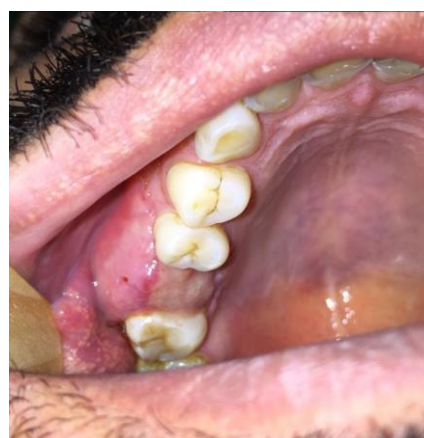

Figure 1: Oroantral fistula at initial clinical examination.

After local anesthesia, an incision was made in the region, complemented by a relaxing incision, with bone support so that the granulomatous inflammatory tissue inside the opening was completely excised (Figure 2).

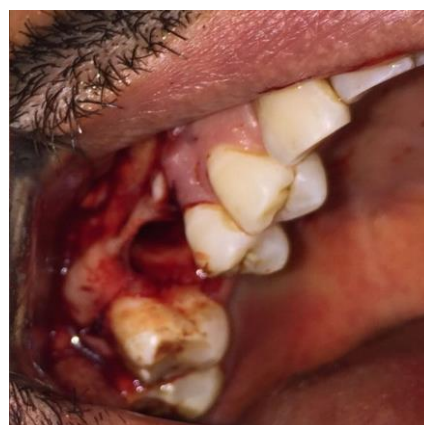

Figure 2: Incision in the surgery field.

After margins regularization, two types of incision were made, horizontal, above the alveolar ridge, and vertical incisions extended to the anterior and posterior buccal sulcus, to provide exposure of the buccal extension of the Bichat's fat-pad that was used as a pediculated graft to close the oroantral fistula (Figure 2).

For the removal of the adipose body, a small incision was made, if it is made large it may cause an excess of lobes out of the adipose body, which will interfere in the surgical field afterwards. After that, the adipose body was manipulated to the side of the surgical defect on the fistula to preserve its thin capsule, and then it was sutured to the palatal mucosa. There should be no suture tensions to avoid periphery tissue necrosis (Figure 3).

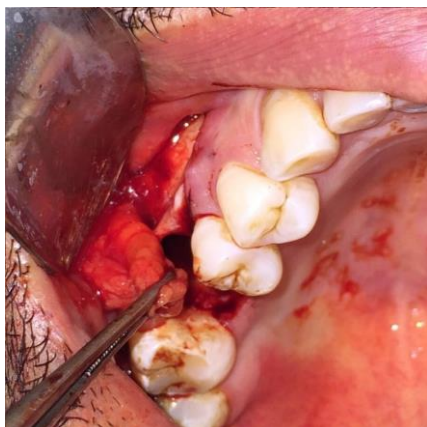


Figure 3: Adipose tissue exeresis.

The mucoperiosteal flap was repositioned in its original position, and the sutures were performed between the adipose body and the oral flap (Figure 4). After adaptation of the adipose body over the bone defect, the suture was performed (Figure 5).

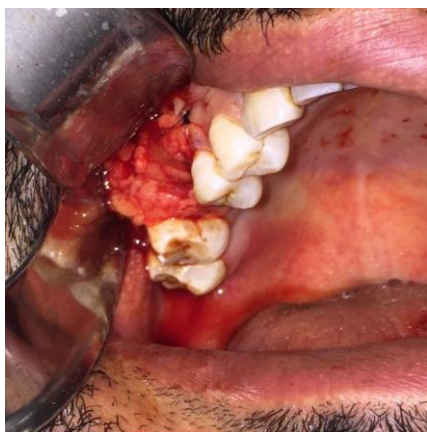

Figure 4: Suture between adipose and gingival tissue.

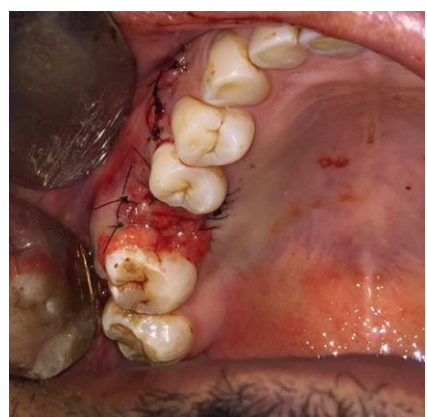


Figure 5: Gingival repositioning and final suture.

Epithelialization of the buccal adipose body graft occurs in 3-4 weeks even without fat covering.

The patient was instructed on the type of diet, which should be light or liquid, medication, oral hygiene and care, such as not smoking in the first week, open his mouth during sneezing, not sucking, avoiding nose blowing and other activities that exert pressure gradient. As a postoperative pharmacological protocol, amoxicillin 500 mg was prescribed every 8 hours for 7 days, and for analgesia, dipyron 500 mg every 6 hours for 2 days. The suture was removed 10 days after the surgical procedure, a complete adaptation of the wound edges and the presence of adipose tissue was observed.

DISCUSSION

The technique of using the buccal adipose body for the closure of oroantral fistulas presents a very low failure rate when performed correctly according to the protocol¹⁶. Otherwise, its use may have some disadvantages¹⁷.

The highest failure rate of the use of the buccal adipose body occurs when there is a necrosis of the adipose tissue, which usually occurs when the suture exerts a great tension on the tissue¹⁸. For this reason, Pereira et al.¹⁹ suggest a tension-free suture to avoid the failure of the procedure. Raldi et al.²⁰ report that the presence of infection or maxillary sinusitis is another condition that causes treatment failure. A fistula will never close with the inflamed sinus, especially when there is purulent discharge, under these conditions, the infection should be treated before surgery²¹⁻²⁵.

Other complications of the use of the buccal adipose body are cases such as hematoma and facial nerve injuries, which can be avoided by careful incision of the buccinator muscle fascia and limited dissection between masticatory spaces²⁶⁻²⁹. Pereira et al.¹⁹ cited the possibility of a depression in the cheek and discreet changes in speech through the use of this technique.

However, Raldi et al.²⁰ disagrees with this statement. Although there are contrary statements regarding the success of this technique, most of the authors certify that the buccal adipose body surgical method presents wide application, great success rate, low risk of infection, being a safe and effective method³⁰⁻³². In addition, the technique of using the buccal adipose tissue for treatment of oroantral communication does not modify the depth of the buccal sulcus avoiding the need of second surgical procedure for prosthodontics rehabilitation of the patient³³.

CONCLUSION

It can be concluded from this study that communications should be treated immediately, if there are signs of inflammation it should be treated first, so that surgical correction can be performed later. In the case reported, the Bichat's fat pad was used for the closure. The technique presented proved

to be safe and effective, providing a comfortable postoperative for the patient, without changing the depth of the buccal sulcus. However, the steps of the procedure must be followed to avoid possible complications.

REFERENCES

1. Camarini ETC, Kamei NC, Farah GJ, Daniel NA, Jacob RJ, Bento LA. Utilização do corpo adiposo bucal para fechamento de comunicação bucosinusal associado à enucleação de cisto residual – relato de caso. *Rev cir traumatol buco-maxilo-fac.* 2007;7(3):23-30.
2. Gallego L, Junquera L, Pelaz A, Hernando J, Megías J. The use of pedicled buccal fat pad combined with sequestrectomy in bisphosphonate-related osteonecrosis of the maxilla. *Med Oral Patol Oral Cir Bucal.* 2012;17(2):e236-41.
3. Dean A, Alamillos F, García-López A, Sánchez J, Peñalba M. The buccal fat pad flap in oral reconstruction. *Head Neck.* 2001;23(5):383-88.
4. Lima LG, Pereira ALC, Matos JDM, Lopes GRS, Vasconcelos JEL, Pita Neto IC. Treatment techniques for oroantral communications and fistulas. *Int J of Dev Res.* 2018;6(7):634-48.
5. Hanazawa Y, Itoh K, Mabashi T, Sato K. Closure of oroantral communications using a pedicled buccal fat pad graft. *J Oral Maxillofac Surg.* 1995;53(7):771-75.
6. Mahajan RK, Chhajlani R, Ghildiyal HC. Role of tongue flap in palatal fistula repair: A series of 41 cases. *Indian J Plast Surg.* 2014;47(2):210-15.
7. Meyer E, Liebenberg SJR, Fagan JJ. Buccal fat pad – a simple, underutilised flap. *S Afr J Surg.* 2012;50(2):47-9.
8. Rause CF, Pruzzo CE, Fonseca AX. Ma15. nejo quirúrgico de la fístula oroantral. *Rev otorrinolaringo Cir cabeza cuello.* 1999;59(2):101-7.
9. Del Rey-Santamaría M, Valmaseda Castellón E, Berini Aytés L, Gay Escoda C. Incidence of oral sinus communications in 389 upper thirmolar extraction. *Med Oral Patol Oral Cir Bucal.* 2006;11(4):E334-38.
10. Tideman H, Bosanquet A, Scott J. Use of the buccal fat pad as a pedicled graft. *J Oral Maxillofac Surg.* 1986;44(6):435-40.
11. Santos IKS, Matos JDM, Barros JD, Medeiros CR, Cariri TFA, Vasconcelos BCG et al. Bichectomy as an alternative treatment for facial harmonization - case report. *Int J of Dev Res.* 2017;5(11):1495-502.
12. Matos JDM, Santos IKS, Perreira ALC, Oliveira AJAG, Vasconcelos BCG, Pita Neto IC et al. The use of the rich fibrin in platelets and leukocytes as alternative treatment for lifting the maxillary sinus - a literature review. *Int J of Dev Res.* 2017;7(6):13436-441.
13. Lima LG, Pereira ALC, Matos JDM, Lopes GRS, Vasconcelos JEL, Pita-Neto IC. Treatment techniques for oroantral communications and fistulas. *Int J of Adv Res.* 2018;6(7):634-48.
14. Awang MN. Closure of oroantral fistula. *Int J Oral Maxillofac Surg.* 1988;17(2):110-15.
15. Borgonovo AE, Berardinelli FV, Favale M, Maiorana C. Surgical options in oroantral fistula treatment. *Open Dent J.* 2012;6(1):94-8.
16. Candamourty R, Jain MK, Sankar K, Babu MRR. Double-layered closure of oroantral fistula using buccal fat pad and buccal advancement flap. *J Nat Sci Biol Med.* 2012;3(2):203-5.
17. Dym H, Wolf JC. Oroantral communication. *Oral Maxillofac Surg Clin North Am.* 2012;24(2):239-47.
18. Magro Filho O, Garbin JREA, Ribeiro JRPD, Felipetti FA. Fechamento de fístula buco-sinusal usando tecido adiposo bucal. *Rev Odontol Bras Central.* 2010;19(50):275-79.
19. Pereira FL, Farah GJ, Passeri LA, Pavan AJ. Aplicação do corpo adiposo bucal para o encerramento de fístula bucosinusal. Relato de caso. *Rev Port Estomatol Cir Maxilofac.* 2004;45:221-26.
20. Raldi FV, Sa-Lima JR, Moraes MB, Zanotti GG. Fechamento de comunicações buco-sinusais - utilização de enxerto pediculado do corpo adiposo bucal. *RGO.* 2006;54(2):178-81
21. Miranda RF, Amorim RH, Rettore Junior R. Tratamento de comunicações buco-sinusais pós-exodontia. *Rev CROMG.* 1999;5(1):60-3.
22. Novais Junior MIL, Almeida MSC, Costa CHM, Sousa Filho LF, Mendes Júnior OR. Uso do corpo adiposo de Bichat para fechamento de comunicação oroantral. *Odontol Clín.-Cient.* 2015;14(3):719-23.
23. Neder A. Use of buccal fat pad for grafts. *Oral surg. Oral Med. Oral Pathol.* 1983;55(4):349-50.
24. Neves EM, Guimarães RES, Bartels VP, Ferreira AC, Pedroso SL. Fechamento de fístula oro-antral com gordura de Bichat. *Rev Bras Cir Craniomaxilofac.* 2009;12(3):125-28.
25. Rahpeyma A, Khajehahmadi S. Posteriorly based lateral tongue flap for reconstruction of large palatal-alveolar fistulas in cleft patients. *Ann Maxillofac Surg.* 2015;5(2):174-78.
26. Rapidis AD, Alexandridis CA, Eleftheriadis E, Angelopoulos AP. The use of the buccal fat pad for reconstruction of oral defects: review of the literature and report of 15 cases. *J Oral Maxillofac Surg.* 2000; 58(2):158-63.
27. Salins PC, Kishore SK. Anteriorly based palatal flap for closure of large oroantral fistula. *Oral Surg Oral Med Oral Pathol Oral Radiol Endod.* 1996;82(3):253-56.
28. Siegel EB, Bechtold W, Sherman PM, Stoopack JC. Pedicle tongue flap for closure of an oroantral

- defect after partial maxillectomy. *J Oral Surgery*. 1977;35(9):746-48.
29. Silveira RL, Santos MESM, Takahashi A, Bourguignon Filho AM, Heitz C. Tratamento de fístula bucosinusal através de retalho palatino. *Rev cir traumatol. buco-maxilo-fac*. 2008;8(1):29-34.
30. Silveira VM, Netto BA, Cósso MG, Fonseca LC. A utilização da tomografia computadorizada na avaliação da comunicação bucosinusal. *Arq bras odontol*. 2008;4(1):24-7.
31. Tideman H, Bosanquet A, Scott J. Use of the buccal fat pad as a pedicled graft. *J Oral Maxillofac Surg*. 1986;44(6):435-40.
32. Watzak G, Tepper G, Zechner W, Monov G, Busenlechner D, Watzek G. Bony press-fit closure of oro-antral fistulas: a technique for pre-sinus lift repair and secondary closure. *J Oral Maxillofac Surg*. 2005;63(9):1288-94.
33. Yalçın S, Öncü B, Emes Y, Atalay B, Aktas I. Surgical Treatment of Oroantral Fistulas: A Clinical Study of 23 Cases. *J Oral Maxillofac Surg*. 2011;69(1):333-39.

CONFLICTS OF INTERESTS

The authors declare no conflicts of interests.

CORRESPONDING AUTHOR

Jefferson David Melo de Matos

Department of Dental Materials and Prosthodontics,
São Paulo State University (Unesp),
Institute of Science and Technology,
São José dos Campos – SP, Brasil
Av. Eng. Francisco José Longo, 777/778, Jardim São Dimas
12245-000 São José dos Campos - SP, Brasil
e-mail: matosjefferson19@gmail.com

Received 17/09/2019

Accepted 08/04/2020