

## Gorlin-Goltz syndrome: systemic and maxillofacial characteristics

*Síndrome de Gorlin-Goltz: características sistêmicas e maxilofaciais*

*Síndrome de Gorlin-Goltz: características sistêmicas y maxilofaciales*

Jefferson David Melo de **MATOS**<sup>1</sup>  
Leonardo Jiro Nomura **NAKANO**<sup>1</sup>  
Pedro Jacy Santos **DIAMANTINO**<sup>1</sup>  
Guilherme da Rocha Scalzer **LOPES**<sup>1</sup>  
Marco Antonio **BOTTINO**<sup>2</sup>  
John Eversong Lucena de **VASCONCELOS**<sup>3</sup>  
Nathália de Carvalho **RAMOS**<sup>4</sup>  
Valdir Cabral **ANDRADE**<sup>5</sup>

<sup>1</sup>Post Graduate Student - Ph.D Program, Department of Dental Materials and Prosthodontics, São Paulo State University (Unesp), Institute of Science and Technology, São José dos Campos - SP, Brazil

<sup>2</sup>Full Professor of Postgraduate Program in Restorative Dentistry, Department of Dental Materials and Prosthodontics, São Paulo State University (Unesp), Institute of Science and Technology, São José dos Campos - SP, Brazil

<sup>3</sup>Professor of Implantology, Department of Dentistry, College of Dentistry CECAPE, Juazeiro do Norte - CE, Brazil

<sup>4</sup>Professor of Prosthodontics, Department of Dentistry, Universidade São Francisco USF, Bragança Paulista - SP, Brazil

<sup>5</sup>Professor Adjunct, Department of Dentistry and Maxillofacial Surgery, Universidade Federal de Juiz de Fora UFJF, Governador Valadares - MG, Brazil

### Abstract

Gorlin-Goltz Syndrome, also known as Nevoid Basal Cell Carcinoma Syndrome, is a rare genetic disorder characterized by the presence of multiple keratocysts in the jaw and basal cell carcinomas, at young age, of palmar and/or plantar depressions, of calcification of the sickle cerebral and skeletal malformations. This syndrome is caused by a mutation of the PTCH1 (patched homolog 1 from Drosophila) gene, a tumor suppressor gene. In this work, the systemic and maxillofacial characteristics of the Gorlin-Goltz syndrome, as well as some neurological, dermatological, musculoskeletal and endocrine alterations, are reviewed. In addition, a case report was added for the purpose of support this study.

**Descriptors:** Basal Cell Nevus Syndrome; Pathology, Oral; Dentistry.

### Resumo

A Síndrome de Gorlin-Goltz, também conhecida como Síndrome do Carcinoma Basocelular Nevoide, é uma desordem genética rara, caracterizada pela presença de queratocistos múltiplos nos maxilares e carcinomas basocelulares, em idade jovem, de depressões palmares e/ou plantares, de calcificação da foice cerebral e de malformações esqueléticas. Esta síndrome é causada por mutação do gene PTCH1 (patched homólogo 1 da Drosophila), um gene supressor tumoral. Nesse trabalho, são revistas em particular as características sistêmicas e maxilofaciais da síndrome de Gorlin-Goltz, bem como algumas alterações, neurológicas, dermatológicas, musculoesqueléticas e endócrinas, ainda foi adicionado um relato de um caso clínico, com o propósito de suporte da pesquisa.

**Descritores:** Síndrome do Nevo Basocelular; Patologia Bucal; Odontologia.

### Resumen

El Síndrome de Gorlin-Goltz, también conocido como Síndrome del Carcinoma Basocelular Nevoide, es un desorden genético raro, caracterizado por la presencia de múltiples ceratocitos en las mandíbulas y carcinomas basocelulares, en edad joven, de depresiones palmares y / o plantares, de calcificación de hoz del cerebro y malformaciones esqueléticas. Este síndrome es causado por la mutación del gen PTCH1 (homología 1 de Drosophila), un gen supresor de tumor. En este trabajo, revisamos en particular las características sistêmicas y maxilofaciales del síndrome de Gorlin-Goltz, así como algunas alteraciones neurológicas, dermatológicas, musculoesqueléticas y endocrinas y un reporte de caso fue incluido con el propósito de respaldar esta investigación.

**Descritores:** Síndrome del Nevo Basocelular; Patología Bucal; Odontología.

### INTRODUCTION

Gorlin-Goltz syndrome was described in 1894 by W Jarisch and JC White, but was only defined as syndrome only 70 years later. It is also known as Gorlin syndrome, basal cell carcinoma syndrome, multiple nevus basalioma syndrome<sup>1,2</sup>.

It is a rare disorder with autosomal dominant inheritance and is characterized by the presence of multiple keratocysts in the jaw, basal cell carcinoma and bifid rib<sup>3,4</sup>. The literature reports a variable prevalence of the syndrome, affecting between 1 in 57,000 and 1 in 164,000 individuals<sup>5</sup>. Gorlin's Syndrome probably appears in all ethnic groups, but has been more commonly reported in white individuals<sup>6</sup>. Literature findings show that men and women are equally affected, and their clinical characteristics arise during the first, second or even the third decade of life<sup>5</sup>.

It is noteworthy that 2% of the population under 45 years presents this syndrome in conjunction with basal cell carcinoma<sup>7</sup>. It results from mutations in the PTCH1 gene (patched homolog 1 of Drosophila) and is transmitted in an autosomal

dominant way with high penetrance and variable expressiveness<sup>8</sup>. Seventy to eighty percent of the patients have an affected parent and 20 to 30% suffer a mutation<sup>9</sup>.

The PTCH1 gene, mapped on chromosome 9 (q22.3-q31), plays a key role in controlling the growth and development of normal tissues<sup>10,11</sup>. Several mutations of the gene have been identified in patients with Gorlin-Goltz syndrome and in patients with basal cell carcinomas and non-hereditary medulloblastomas<sup>9</sup>.

The gene product is a transmembrane protein component (Ptc), which in the presence of the Sonic Hedgehog protein activates another transmembrane protein component (Smo, from smoothed). Activation of the latter promotes the transcription in certain cells of genes encoding signaling proteins belonging to the families of TGF-beta (transforming growth factor beta) and Wnt (wingless-type MMTV integration site), facilitating cell growth and differentiation processes<sup>11</sup>.

The molecular biology of neoplasms in the

Gorlin-Goltz syndrome follows the Knudson theory of the two events. Patients with the syndrome have a constitutional defect in the DNA sequence in one of two copies of the tumor suppressor gene, insufficient to allow the development of a neoplasm. A defect or loss of the remaining normal allele occurs and the cell may then become malignant<sup>12</sup>.

The most common clinical manifestations include basal cell carcinomas (basaliomas) of early onset, odontogenic keratocysts, palmar and / or plantar depressions (rarely present in children), ectopic calcifications of cerebral sickle and congenital skeletal anomalies<sup>9,11</sup>.

The keratocystic odontogenic tumors (KOTs) appear in more than 75% of the patients who have the syndrome, and may be one of the first characteristics to be diagnosed by means of radiographic findings or clinical manifestations<sup>13-16</sup>. This fact makes necessary to diagnose early, due to possible complications, among them the occurrence of brain and epithelial malignant tumors<sup>17</sup>.

Most KOTs occur in the posterior portion of the mandible body and in the branch region. Lesions in the upper arch are noted mainly in the third molar area, then in the canine region<sup>15,16</sup>. These cysts present a recurrence rate of more than 62%, especially in the first five years after surgical treatment<sup>4,6</sup>.

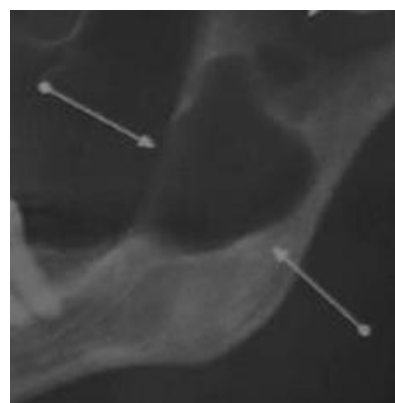
Therapy for keratocystic odontogenic tumors may range from enucleation with curettage, enucleation with peripheral osteotomy or block bone resection<sup>14,18</sup>.

Based on the above mentioned information, the objective of this work is to report a clinical case of a patient with Gorlin-Goltz Syndrome, who underwent conservative therapy for treatment of recurrent KOTs, in which it has been followed for 24 months.

### CLINICAL CASE

A 33-year-old female patient, leucoderma, attended the dental clinic of the Juazeiro do Norte College of Dentistry CECAPE, with variation in the face and presence of frontal and temporoparietal bossa, resulting in increased cranial circumference, eyes were separated and mild ocular hypertelorism, epidermoid cysts on the skin, palmoplantar depressions, occult spina bifida of the cervical vertebrae, and mild mandibular prognathism are also often present with multiple jaw lesions. Panoramic radiographic examination revealed radiolucent areas in the mandible, involving both branches and maxilla (Figure 1). The patient brought the report of the clinic of oral dysmorphology with clinical diagnosis of Gorlin's Syndrome, where genetic counseling was made and the need for medical follow-up was recommended. Evans and contributors in 1993 presented a series of criteria for the diagnosis of this

syndrome<sup>19</sup>, which were modified by Kimonis et al.<sup>20</sup>, in which they include larger and smaller criteria, according to which authors would only need two major or two minor criteria and one bigger for the diagnosis of the syndrome (Table 1).

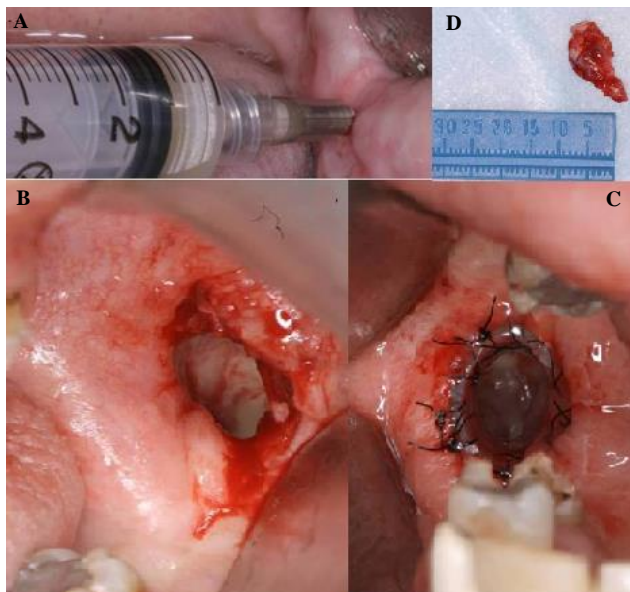


**Figure 1:** Preoperative orthopantomography showing the presence of keratocyst in the posterior region of the right side of the jaw.

**Table 1.** Major criteria for the diagnosis of Gorlin-Goltz syndrome

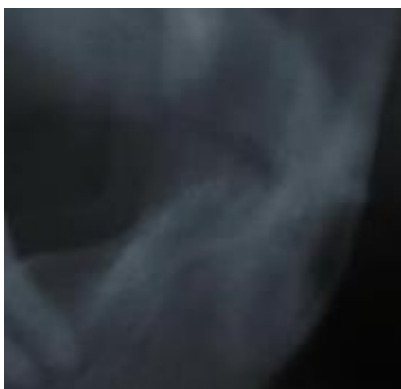Diagnostic criteria of Gorlin-Goltz Syndrome	
<b>Major criteria</b>	
Two or more basal cell carcinomas or one less than 20 years old	
Odontogenic keratocysts with histological evidence	
Three or more palm or plantar depressions	
Brain sickle bilamellar calcification	
Bifid, cast or flat ribs	
First-degree relatives with Gorlin-Goltz syndrome	

In this way, cystic decompression was planned for the region of the elements 22, 28 and left jaw branch under local anesthesia and periodic follow-up, in which the histopathological examination revealed sinus epithelium, without signs of injury, in which maxilla orifices were closed and odontogenic keratocyst in the mandible (Figure 2). She was maintained in clinical and radiographic monitoring where it showed a good resolution of the case with the passage of time, seen by the radiographic examination an image suggestive of bone neoformation. After a while the patient began to miss the return visits, and / or when she went; did not perform the image examination requested for postoperative follow-up, until in December 2011 the patient sought a dentist in her city for dental treatment one observed, during the radiographic examination, the presence of radiolucent images. After this, a tomography was requested with radiographic report, in which was showed the presence of multiple odontogenic keratocysts in the maxilla and mandible suggesting histological examination of the hypodense lesions present in the maxilla and mandible and clinical evaluation; in the biopsy report, was a remark by the pathologist advising that the presence of the Gorlin syndrome needed to be investigated.



**Figure 2:** Incisional biopsy, with marsupialization maneuver of the lesion in the posterior region of the mandibular ramus.

In this way the clinician referred the patient to our service, and no volume increase was observed in the face, with cutaneous lesions on the upper lip, slow growth according to the patient, with defined limits, spherical shape of reddish color with one month of evolution. A new decompression of the left branch was planned, as well as removal of the cutaneous lesion for anatomic-pathological analysis and periodic follow-up. The specimens were sent for histopathological examination. The result of mandibular lesion biopsy confirmed the diagnosis of odontogenic keratocyst in the mandible, the following description was presented in the report: dense fibrous tissue and chronic inflammatory infiltrate in the premaxilla region and basal cell carcinoma of the biopsied material in the upper lip. Regarding these skin lesions, the patient was referred to the dermatologist and the removal of the lesions was performed, and she was accompanied by eventual skin lesions. After this, the patient was examined at periodic visits with clinical and radiographic examination and no recurrence or "new" lesion was found in the area adjacent to the first intervention (Figure 3).



**Figure 3:** Postoperative radiographic examination, after removal of the drain.

## DISCUSSION

Our patient presented the histologically proven odontogenic keratocysts and more than two basal cell carcinomas as the major criteria for Gorlin-Goltz syndrome; as minor criteria, skeletal anomalies (frontal bossa), and already have the genetic evidence of the syndrome. The patient did not have a current family history to have the syndrome. In this context, it is necessary to perform a complete family genetic screening, that is, to make a complete mapping of the family genetic code. This test is theoretically indispensable, but it is not something used in clinical practice<sup>19,20</sup>.

Basal cell carcinomas may appear early, with reports at two years of age, but their diagnosis is averaged at age 251. Corroborating our case, because the patient who was older than the one mentioned in the literature. The incidence of carcinomas in the Gorlin-Goltz syndrome varies significantly between ethnic groups: 40% in black patients and 90% in Caucasians<sup>1,9</sup>.

The keratocystic odontogenic tumors account for 10 to 12% of all maxillary cysts, and about 5% are associated with Gorlin's Gorlin syndrome<sup>20</sup>. They are called keratocysts because they have a thin fibrous outer capsule with a parakeratinized squamous stratified epithelium inner lining. Keratocysts are developmental odontogenic cysts and develop from remnants of the dental blade and the enamel organ epithelium, are uni or multilocular and are located at the site of a normal or supernumerary tooth. Keratocysts can be found near the canine teeth or at the angle of the jaw without apparent contact with the alveolar crest. They appear in 75% of the syndromic patients and are usually the first evidence signs<sup>6,17</sup>. They are usually multiple and asymptomatic, and may be present in any region of maxillary bones<sup>14,15</sup>.

Differential diagnosis should include follicular cyst, unicystic ameloblastoma, odontogenic fibromixoma, and residual cysts. In the context of Gorlin-Goltz syndrome, keratocysts are multiple (on average five, and may be present between one and thirty) and are detected in patients less than 10 years old. Thirteen percent of these patients develop a cyst at 10 years and 51% at 20 years<sup>19,21</sup>. There is a continuous development of new and recurrent cysts up to 30 years of age, when it begins to develop less frequently<sup>22</sup>. The most common location is between the molar teeth and the mandible branch (44%), followed by the region between the incisor and canine teeth (18%)<sup>9</sup>. Cysts can reach large dimensions, especially when the jaw branch is hit. About 50% of the patients present with swellings that can condition tooth dislocation, 25% with moderate pain. Occasionally maxillary fractures may occur. Rarely, ameloblastomas or pavement cell carcinoma



may occur in keratocysts<sup>23,24</sup>. In our case, the cysts were located in the region of the bilateral mandibular branch with a size of approximately 4 cm, however, there was no fracture of the localized body region.

There are multiple treatment techniques that include curettage enucleation, enucleation with peripheral osteotomy, and block bone resection, among which the latter technique is seen as aggressive<sup>3,6,17</sup>. There are other techniques considered conservative, such as cryotherapy, cyst marsupialization or decompression followed by secondary enucleation<sup>6</sup>. The choice for therapy depends on the size, location and extent of the lesion, as well as on the age and the fact that the lesion is primary or recurrent<sup>17,25</sup>.

In the present case, the technique of decompression followed by enucleation with secondary curettage has been used with some frequency and is a technique that has been suggested in the literature as an efficient method<sup>3,5,26</sup>. The recurrent character of the cyst is emphasized by several studies<sup>4,6,9,25</sup>.

Among other maxillofacial problems include dental malocclusion, mandibular prognathism, ectopies or dental heterotopias and dental agenesis; the lip and palate cleft are rares. Bilateral hyperplasia of the coronoid apophyses, when present in a child, is indicative of the syndrome<sup>13,27</sup>. In our case the patient presented lesions on the skin, frontal bossa, dental malocclusion and irregular border.

Between 70-85% of Gorlin-Goltz syndrome cases have lamellar calcification of the cerebral scythe. This calcification usually does not cause symptoms but corroborate the diagnosis. The syndrome may also have brain abnormalities such as: choroid plexus cysts of the third ventricle and lateral ventricles, intraparenchymal cysts, arachnoid cysts, glial nodules, corpus callosum agenesis with or without associated lip saddle, communicating hydrocephalus septum, pellucid septum cysts and brain tumors<sup>12,20,28</sup>.

Medulloblastoma has an incidence of 1 to 2% in the Gorlin-Goltz syndrome and is present in the first two years of life, preferably in male patients<sup>3,29</sup>. Intracranial tumors associated with Gorlin-Goltz syndrome are meningioma and, more rarely, astrocytoma, craniopharyngioma and oligodendroglioma<sup>9</sup>.

However, Blanas et al. questions this statement, reporting that the recurrence of these odontogenic cysts in syndromic patients may mean induction of the development of new cyst formation, which significantly increases the recurrence rate in a given treatment. According to these authors, in the reported case, we cannot say that the surgical decompression procedure consisted of recurrent cysts or new cysts, but rather a surgical management that allows the creation of a surgical window in the cyst

wall, emptying the contents and maintaining continuity. between the cyst and the oral cavity, the only part removed is for the making of the window. Consecutively this procedure decreasing the intracystic pressure promoting the reduction of the cyst size as the bone filling<sup>25</sup>.

Radiographic examination 15 months after the first intervention revealed a radiolucent lesion in the area of the keratocysts removed, and our intervention was done in the same location (right ascending branch of the mandible).

The radiographic findings of the cysts occurred during the first 24 months after the initial surgical procedure, indicating a recurrence of this cyst in the first five years<sup>4,30</sup>. Previous publications have reported recurrences up to 41 years after the first treatment<sup>31</sup>.

According to the literature, recurrence can be explained by the type of coating and / or presence of the satellite cyst within its capsule and by the possibility of perforation and expansion of the bone cortical as well as of penetration into the bone base<sup>3,15,16,20,26,31</sup>.

## CONCLUSION

It can be concluded from this study that the diagnosis and treatment of Gorlin Goltz syndrome requires multidisciplinary approach by dermatologists, plastic surgeons, dentists, head and neck surgeons, neurologists and neurosurgeons. Genetic burden assessment and family screening are essential. It is necessary to be aware of the extreme sensitivity of these patients in relation to ionizing radiation, with potential for the development of multiple neoplasms, particularly basal cell carcinomas, meningiomas. Taking into account the limitations of the present study, further studies are needed to properly understand the best approach for these cases.

## REFERENCES

1. Gorlin RJ, Goltz RW. Multiple nevoid basal-cell epithelioma, jaw cysts and bifid rib: a syndrome. *N Engl J Med.* 1960;262(18):908-12.
2. Bale AE. The nevoid basal cell carcinoma syndrome: genetics and mechanism of carcinogenesis. *Cancer Invest.* 1997;15(2):180-86.
3. Addessi G, Del Vecchio A, Maggiore C, Ripari M. Gorlin's Syndrome: case report. *Minerva Stomatol.* 2002;51(4):145-9.
4. Amezaga AOG, Arregui OG, Nuño SZ, Sagredo AA, Aguirre JM. Gorlin-Goltz syndrome: clinicopathologic aspects. *Med Oral Patol Oral Cir Bucal.* 2008;13(6):338-43.
5. Medeiros L, Ferreira JC. Síndrome de Gorlin-Goltz: revisão bibliográfica a propósito de um caso clínico. *Rev Port Estomatol Cir Maxilofac.* 2006;47(1):25-32.
6. Manfredi M, Vescovi P, Bonanini M, Porter S.

- Nevoid basal cell carcinoma syndrome: a review of the literature. *Int J Oral Maxillofac Surg.* 2004;33(2):117-24.
7. Rahbari H, Mehregan AH. Basal cell epithelioma (carcinoma) in children and teenagers. *Cancer.* 1982;49(2):350-53.
  8. Bialer M, Gailani M, McLaughlin J, Petrikovsky B, Bale A. Prenatal diagnosis of Gorlin syndrome. *Lancet.* 1994;344(8920):477.
  9. Muzio LL. Nevoid basal cell carcinoma syndrome (Gorlin syndrome). *Orphanet J Rare Dis.* 2008;3(1):32-47.
  10. Farndon PA, Del Mastro RG, Kilpatrick MW, Evans DRG. Location of gene for Gorlin syndrome. *Lancet.* 1992;339(8793):581-82.
  11. Wicking C, Bale AE. Molecular basis of the nevoid basal cell carcinoma syndrome. *Curr Opin Pediatr.* 1997;9(6):630-35.
  12. Ratcliffe JF, Shanley S, Ferguson J, Chenevix-Trench G. The diagnostic implication of falcine calcification on plain skull radiographs of patients with basal cell naevus syndrome and the incidence of falcine calcification in their relatives and two control groups. *Br J Radiol.* 1995;68(808):361-68.
  13. Ruprecht A, Austermann KH, Umstadt H. Cleft lip and palate, seldom seen features of the Gorlin-Goltz syndrome. *Dentomaxillofac Radiol.* 1987;16(2):99-103.
  14. Barnes L, Eveson JW, Reichart P, Sidransky D. World Health Organization classification of tumours. Pathology and genetics of head and neck tumours. Lyon: IARC Press; 2005.
  15. Veenstra-Knol HE, Scheewe JH, Van Der Vlist GJ, Van Doorn ME, Ausems MG. Early recognition of basal cell naevus syndrome. *Eur J Pediatr.* 2005;164(3):126-30.
  16. Gu XM, Zhao HS, Sun LS, Li TJ. PTCH mutations in sporadic and Gorlin-syndrome-related odontogenic keratocysts. *J Dent Res.* 2006;85(9):859-63.
  17. Díaz-Fernández JM, Infante-Cossío P, Belmonte-Caro R, Ruiz-Laza L, García-Perla-García A, Gutiérrez-Pérez JL. Basal cell nevus syndrome. Presentation of six cases and literature review. *Med Oral Patol Oral Cir Bucal.* 2005;10(1):57-66.
  18. Friedrich RE. Diagnosis and treatment of patients with nevoid basal cell carcinoma syndrome [Gorlin-Goltz syndrome (GGS)]. *Anticancer Res.* 2007;27(4):1783-87.
  19. Evans DG, Ladusans EJ, Rimmer S, Burnell LD, Thakker N, Farndon PA. Complications of the naevoid basal cell carcinoma syndrome: results of a population based study. *J Med Genet.* 1993;30(6):460-64.
  20. Kimonis VE, Goldstein AM, Pastakia B, Yang ML, Kase R, DiGiovanna JJ, et al. Clinical manifestations in 105 persons with nevoid basal cell carcinoma syndrome. *Am J Med Genet.* 1997;69(3):299-308.
  21. Shanley S, Ratcliffe J, Hockey A, Haan E, Oley C, Ravine D, et al. Nevoid basal cell carcinoma syndrome: review of 118 affected individuals. *Am J Med Genet.* 1994;50(3):282-90.
  22. Mustaciulo VW, Brahney CP, Aria AA. Recurrent keratocysts in basal cell nevus syndrome: review of the literature and report of a case. *J Oral Maxillofac Surg.* 1989;47(8):870-73.
  23. Schultz SM, Twickler DM, Wheeler DE, Hogan TD. Ameloblastoma associated with basal cell nevus (Gorlin) syndrome: CT findings. *J Comput Assist Tomogr.* 1987;11(5):901-4.
  24. Hasegawa K, Amagasa T, Shioda S, Kayano T. Basal cell nevus syndrome with squamous cell carcinoma of the maxilla: report of a case. *J Oral Maxillofac Surg.* 1989;47(6):629-33.
  25. Blanas N, Freund B, Schwartz M, Furst IM. Systematic review of the treatment and prognosis of the odontogenic keratocyst. *Oral Surg Oral Med Oral Pathol Oral Radiol Endod.* 2000;90(5):553-58.
  26. Myoung H, Hong SP, Hong SD, Lee JI, Lim CY, Chung PH, et al. Odontogenic keratocyst: review of 256 cases for recurrence and clinicopathologic parameters. *Oral Surgery, Oral Medicine, Oral Pathology, Oral Radiology and Endodontics.* 2001;91(3):328-33.
  27. Leonardi R, Caltabiano M, Lo Muzio L, Gorlin RJ, Bucci P, Pannone G, et al. Bilateral hyperplasia of the mandibular coronoid processes in patients with nevoid basal cell carcinoma syndrome: an undescribed sign. *Am J Med Genet.* 2002;110(4):400-3.
  28. Takanashi JI, Fujii K, Takano H, Sugita K, Kohno Y. Empty sella syndrome in nevoid basal cell carcinoma syndrome. *Brain Dev.* 2000;22(4):272-74.
  29. Amlashi SF, Riffaud L, Brassier G, Morandi X. Nevoid basal cell carcinoma syndrome: relation with desmoplastic medulloblastoma in infancy. *Cancer.* 2003;98(3):618-24.
  30. Ramaglia L, Morgese F, Pighetti M, Saviano R. Odontogenic keratocyst and uterus bicornis in nevoid basal cell carcinoma syndrome: case report and literature review. *Oral Med Oral Pathol Oral Radiol Endod.* 2006;102(2):217-19.
  31. Zhao YF, Wei JX, Wang SP. Treatment of odontogenic keratocysts: a follow-up of 255 Chinese patients. *J Oral Maxillofac Surg.* 2002;64(2):151-56.

### CONFLICTS OF INTERESTS

---

The authors declare no conflicts of interests.

### CORRESPONDING AUTHOR

---

**Jefferson David Melo de Matos**

Department of Dental Materials and Prosthodontics,  
São Paulo State University (Unesp)  
Institute of Science and Technology  
São José dos Campos – SP, Brasil  
Av. Eng. Francisco José Longo, 777/778  
Jardim São Dimas  
12245-000 São José dos Campos - SP, Brasil  
e-mail: matosjefferson19@gmail.com

**Received** 13/11/2019

**Accepted** 22/10/2020