

Extra-articular Distal Humerus Bridging Plate: a Minimally Invasive Technique

Placa de Ponte do Úmero Distal Extra-Articular: uma Técnica Minimamente Invasiva

Placa Puente Extrarticular para Húmero Distal: una Técnica Mínimamente Invasiva

Luis Guilherme Rosifini Alves **REZENDE**

Hand Surgeon, Microsurgeon and Upper Limb Surgeon at the Department of Orthopaedics and Anesthesiology of the Ribeirão Preto Medical School at the University of São Paulo, Ribeirão Preto, São Paulo, Brazil
<https://orcid.org/0000-0002-2037-0135>

Filipe Jun **SHIMAOKA**

Hand Surgeon, Microsurgeon and Upper Limb Surgeon at the Department of Orthopaedics and Anesthesiology of the Ribeirão Preto Medical School at the University of São Paulo, Ribeirão Preto, São Paulo, Brazil
<https://orcid.org/0000-0002-1475-1396>

Luiz Garcia **MANDARANO-FILHO**

Hand Surgeon, Microsurgeon and Upper Limb Surgeon at the Department of Orthopaedics and Anesthesiology of the Ribeirão Preto Medical School at the University of São Paulo, Ribeirão Preto, São Paulo, Brazil
<https://orcid.org/0000-0002-2774-9471>

Nilton **MAZZER**

MD, PhD, Chairman, Full Professor, Surgery of the Hand and Upper Limb - Microsurgery. Orthopaedic - Ribeirão Preto Medical School at the University of São Paulo, Ribeirão Preto, São Paulo, Brazil
<https://orcid.org/0000-0002-1239-7602>

Abstract

Extra-articular fractures of the distal humerus are challenging due to their peculiar location and anatomy. It challenges the surgeon to choose the best osteosynthesis method and approach. We present a minimally invasive technique by bridging the LCP Extra-articular distal humerus plate (DePuy-Synthes). The indication for this method was fractures classified as AO/OTA type 13A2 and 13A3. Concerns about the radial nerve pathway to avoid its injury are crucial to perform this method. Possible complications are shortening, rotational displacement, nerve injury and wrong plate and screw positioning.

Descriptors: Humerus; Humeral Fractures; Orthopedic Fixation Devices.

Resumo

As fraturas extra-articulares do úmero distal são desafiadoras devido à sua localização e anatomia peculiares. Desafia o cirurgião a escolher o melhor método e abordagem de osteossíntese. Apresentamos uma técnica minimamente invasiva através da ponte da placa úmero distal extra-articular do LCP (DePuy-Synthes). A indicação desse método foram as fraturas classificadas como AO/OTA tipo 13A2 e 13A3. A preocupação com o trajeto do nervo radial para evitar sua lesão é fundamental para a realização deste método. As possíveis complicações são encurtamento, deslocamento rotacional, lesão do nervo e posicionamento incorreto da placa e do parafuso.

Descritores: Úmero; Fraturas do Úmero; Dispositivos de Fixação Ortopédica.

Resumen

Las fracturas extraarticulares del húmero distal son un desafío debido a su ubicación y anatomía peculiares. Desafia al cirujano a elegir el mejor método y abordaje de osteosíntesis. Presentamos una técnica mínimamente invasiva mediante el puente de la placa de húmero distal extraarticular LCP (DePuy-Synthes). La indicación de este método fueron las fracturas clasificadas como AO/OTA tipo 13A2 y 13A3. Las preocupaciones sobre la vía del nervio radial para evitar su lesión son cruciales para realizar este método. Las posibles complicaciones son el acortamiento, el desplazamiento rotacional, la lesión del nervio y la colocación incorrecta de la placa y el tornillo.

Descritores: Húmero; Fracturas del Húmero; Dispositivos de Fijación Ortopédica.

INTRODUCTION

The distal humerus fracture challenges orthopedic surgeons due to its complexity and uncommon routine—the complex anatomy bewilders the management and the choice of the osteosynthesis method and approach. Even the most experienced surgeons have hardship if they minimize their complexity because of unexpected comminution and bone stock¹. Distal humerus fractures account for 0.6 to 2% of all fracture types in a bimodal pattern, being the extra-articular more common. The younger group has a high energy pattern between 21 and 30. The Elderly Group has a low-energy pattern (fall from the height) between 60 and 80 years old²⁻⁴.

The gold standard is open reduction and internal fixation (ORIF) of the extra-articular fractures. Thus, allowing immediate bone stabilization, early range of motion and decreasing the complications of the non-operative management. However, there are complications as infection, iatrogenic nerve

injury, and the possibility of more surgical operations^{5,6}.

Extra-articular fractures management requires bone stabilization and rotational resistance forces, allowing shoulder and elbow active range of motion. Regardless, the fracture site should select the osteosynthesis device method and approach.⁵ Diaphyseal humerus fractures are usually managed with straight 3.5 or 4.5mm plates and screws. But they are not suitable for low diaphyseal fracture patterns or "extra-articular distal humerus fractures). These situations claim to use orthogonal plates or parallel plates (anatomic pre-fabricated shaped versus hand-molded). Remark that underdeveloped countries sometimes need to use a self-hand-molded plate.^{5,6}

The current approach is widely open to expose the fracture focus, which morbidity decreases local vascular supply. It's painful and cares the risk of infection and wound complications. It could delay the rehabilitation

protocol. Many authors described good outcomes for managing diaphyseal humerus fractures with minimally invasive methods⁷⁻¹¹.

These techniques have less soft tissue damage, higher union rates and low infection rates. However, they do not allow radial nerve identification.¹² Given this, many authors are concerned about the radial nerve¹³⁻¹⁶.

Furthermore, the minimally invasive technique for the distal humerus has several disadvantages: the cylindrical and thick in its diaphysis and the thin and triangular epiphysis. Therefore, it has a small area to place the screws and fixation points¹⁷.

We used the LCP Extra-articular distal humerus plate (DePuy Synthes®, West Chester, PA) to manage these fractures for the last five years. This plate shapes the distal humerus's posterolateral anatomy, providing distal and proximal fixation holes¹⁸⁻²⁰.

This study aims to describe a minimally invasive technique modification to internal fixation of the extra-articular distal humerus fracture using the DePuy Synthes.

TECHNIQUE AND APPROACH

The patient is positioned in a lateral position with the elbow placed in an arm-holder, using two approaches in the skin.

The proximal approach is landmarked 10 centimeters distal to the posterolateral angle of the acromion process. A five-centimeter incision is made over the proximal skin, and the interval between the long and the lateral triceps brachii heads and the posterior deltoid border is developed. At this point, the radial nerve is identified and carefully protected. A sliding tunnel is developed using a finger or rugine in a distal direction (Figure 1 and 2A).

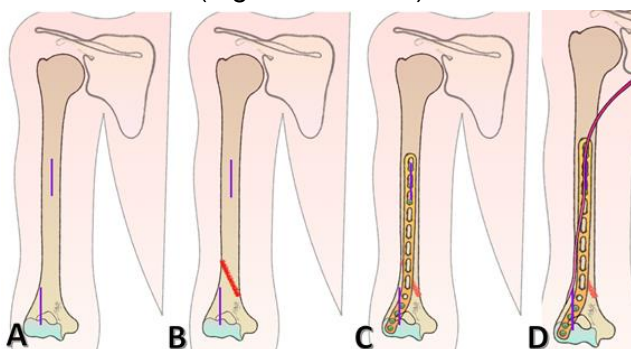


Figure 1: Landmarks and plate placement. A. Proximal and Distal Incisions. B. Fracture line (red). C. Extra-articular plate positioned. D. Radial nerve pathway (purple). Copyright: Luis Guilherme Rosifini Alves Rezende, 2022.

The distal approach is a five-centimeter landmarked straight incision at the level of the posterior humerus. It's placed two centimeters lateral to the olecranon fossa (or to the tip of the olecranon). The triceps aponeurosis is dissected until the lateral column is visualized (Figure 2B)

The pathway of the radial nerve is from medial to posterior 20 centimeters above the lateral epicondyle, lying over the site of the proximal plate. It runs over the posterior surface of the humerus, crossing from posterior to lateral (and anterior) by 11 to 14 centimeters over the lateral epicondyle. Awareness of these parameters is essential to avoid iatrogenic injury.

The fracture is reduced, and the plate is inserted distal to proximal. It's essential to avoid shortening of rotational displacement and radial nerve impingement. The plate is placed on the posterior surface of the humerus at the proximal level. It's left in the lateral column, at the level of the olecranon fossa. The plate acts as a bridging plate. (Figure 2C).

The most distal 3.5mm locked screw is first placed, followed by the most proximal 3.5mm locked (or don't if the plate is well placed). Two more screws are placed in the proximal and three or four in the distal holes.

The use of fluoroscopy allows implant and fracture correct positioning. Avoid placing screws into the olecranon fossa. Hemostasia is carefully performed, and the wound is closed. Early ROM is then allowed, but we don't advise resisted shoulder rotational motion in the first two weeks. Figures 3 and 4 present the final aspect of the bridging plate in a comminuted fracture and one of a simple fracture.

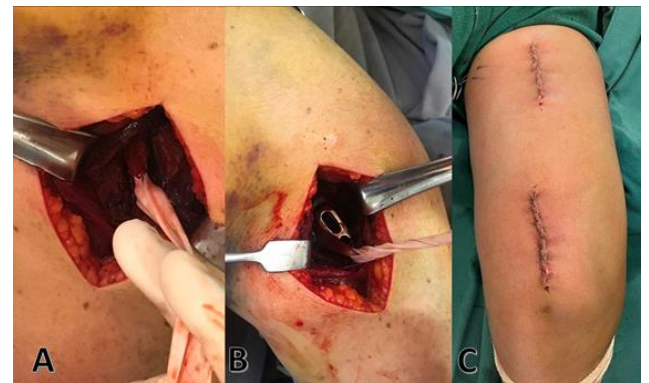

Figure 2: Intraoperative steps. A. Radial nerve identification. B. Proximal plate positioning. C. final wound aspect.

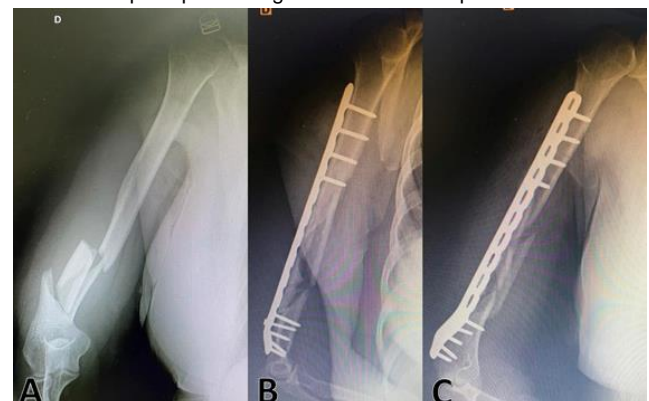


Figure 3: Extra-articular comminuted distal humerus fracture. A. Preoperative anteroposterior view. B. postoperative oblique and C. Postoperative lateral view.

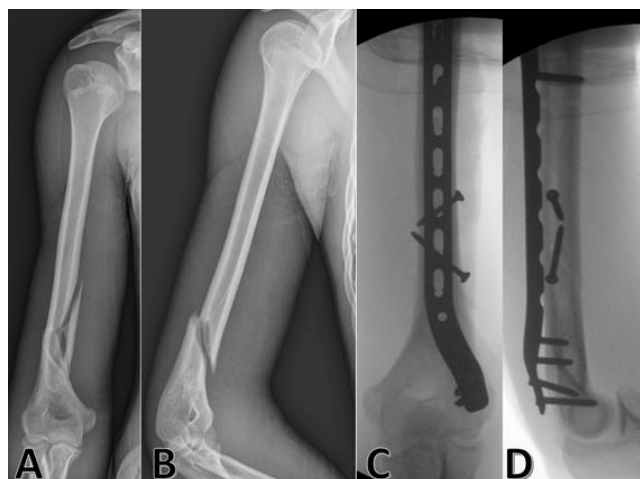


Figure 4: Extra-articular distal humerus fracture. Preoperative anteroposterior (A) and lateral (B) views. Postoperative anteroposterior (C) and lateral (D) view.

DISCUSSION

The extra-articular bridging plate is a method to manage fractures classified as A1. The concerns about radial nerve injury remain as a disadvantage for this method. However, bridging plate techniques are faster and easy to reproduce¹⁸⁻²⁵.

However, they depend on surgeon expertise. Indeed, we don't advise younger surgeons to perform this technique. Distal humerus fractures are challenging, and there are many complications and technical details to manage them. The possible complications of the procedure are humerus shortening, rotational displacement and radial nerve injuries. They could be avoided using the step-by-step described earlier¹⁸⁻³⁹.

This technique best addresses distal humerus fractures classified by AO/OTA Classification System 13A2 and 13A3. In this case, we opte

Regardless, distal humerus fractures have many complications reported that should be awarded to the patient. Elbow stiffness, loss of full range of motion, infection, wound disturbances and nerve injury are expected in all osteosynthesis methods^{22,28,31-39}.

The AO Group standard technique described for this plate differs from the bridging plate method described here. It was described as the conventional broad and open approach exposure. However, it isn't exempt from risks and complications. Thus, we don't advise this technique for early beginners or surgeons who don't are familiar with this plate or use the distal humerus posterior approach.

CONCLUSION

We conclude that the minimally invasive posterior bridging plate using the LCP Extra-articular distal humerus plate (DePuy-Synthes)

system is an alternative to extra-articular distal humerus fractures.

REFERENCES

1. Riseborough EJ, Radin EL: Intercondylar T fractures of the humerus in the adult: a comparison of operative and non-operative treatment in twenty-nine cases. *J Bone Joint Surg Am* 1969;51:130-41.
2. Tytherleigh-Strong G, Walls N, McQueen MM. The epidemiology of humeral shaft fractures. *J Bone Joint Surg Br.* 1998;80(2):249-53.
3. Robinson CM, Hill RM, Jacobs N, Dall G, Court-Brown CM. Adult distal humeral metaphyseal fractures: epidemiology and results of treatment. *J Orthop Trauma.* 2003;17(1):38-47.
4. Rockwood CA Jr, Green DP, Bucholz RW, Heckman JD. *Rockwood and Green's fractures in adults.* 7th ed. Philadelphia: Lippincott Co; 2013
5. Scolaro JA, Hsu JE, Svach DJ, Mehta S. Plate selection for fixation of extra-articular distal humerus fractures: A biomechanical comparison of three different implants. *Injury, Int. Care Injured* 2014;45:2040-44.
6. Jawa A, Harris M, Ring D. Extra-articular distal-third diaphyseal fractures of the humerus. A comparison of functional bracing and plate fixation. *J Bone Joint Surg Am* 2006;88(11):2343-47.
7. Xuqi HU, Siqi XU, Huigen LU, Bao C, Xiao Z, Xiaojun H. Minimally invasive plate osteosynthesis vs conventional fixation techniques for surgically treated humeral shaft fractures: a meta-analysis. *J Orthop Surg Res.* 2016;11:59.
8. Ji F, Tong D, Tang H, Cai X, Zhang Q, Li J. Minimally invasive percutaneous plate osteosynthesis (MIPPO) technique applied in the treatment of humeral shaft distal fractures through a lateral approach. *Int Orthop.* 2009;33(2):543-47.
9. Shin SJ, Sohn HS, Do NH. Minimally invasive plate osteosynthesis of humeral shaft fractures: a technique to aid fracture reduction and minimize complications. *J Orthop Trauma.* 2012;26(10):585-89.
10. Kobayashi M, Watanabe Y, Matsushita T. Early full range of shoulder and elbow motion is possible after minimally invasive plate osteosynthesis for humeral shaft fractures. *J Orthop Trauma.* 2010;24(4):212-16.
11. Lopez-Arevalo R, de Llano-Temboury AQ, Serrano-Montilla J, de Llano-Gimenez EQ, Fernandez-Medina JM. Treatment of diaphyseal humeral fractures with minimally invasive percutaneous plate (MIPPO) technique: a cadaveric study and clinical results. *J Orthop Trauma.* 2011;25(5):294-99.
12. Zhiquan A, Bingfang Z, Yeming W, Chi Z, Peiyan H. Minimally invasive plating

- osteosynthesis (MIPO) of middle and distal third humeral shaft fractures. *J Orthop Trauma*. 2007;21(9):628-33.
13. Esmailiejah AA, Abbasian MR, Safdari F, Ashoori K. Treatment of Humeral Shaft Fractures: Minimally Invasive Plate Osteosynthesis Versus Open Reduction and Internal Fixation. *Trauma Mon*. 2015;20(3): e26271.
 14. Siegel J, Tornetta P3, Borrelli JJ, Kregor P, Ricci WM. Locked and minimally invasive plating. *Instr Course Lect*.2007;56:353-68.
 15. An Z, Zeng B, He X, Chen Q, Hu S. Plating osteosynthesis of mid-distal humeral shaft fractures: minimally invasive versus conventional open reduction technique. *Int Orthop*. 2010;34(1):131-35.
 16. Livani B, Belangero W, Andrade K. Is MIPO in humeral shaft fractures really safe? Postoperative ultrasonographic evaluation. *Int Orthop (SICOT)* 2009;33:1719-23.
 17. Prasarn ML, Ahn J, Paul O, Morris EM, Kalandiak SP, Helfet DL. Dual plating for fractures of the distal third of humeral shaft. *J Orthop Trauma* 2011;25(1):57-63.
 18. Levy JC, Kalandiak SP, Hutson JJ, Zych G. An alternative method of osteosynthesis for distal humeral shaft fractures. *J Orthop Trauma* 2005;19(1):43-7.
 19. Scolaro JA, Voleti P, Makani A, Namdari S, Mirza A, Mehta S. Surgical fixation of extra-articular distal humerus fractures with a posterolateral plate through a triceps-reflecting technique. *J Shoulder Elbow Surg* 2014;23(2):251-57.
 20. Capo JT, Debkowska MP, Liporace F, Beutel BG, Melamed E. Outcomes of distal humerus diaphyseal injuries fixed with a single-column anatomic plate. *Int Orthop* 2014;38(5):1037-43.
 21. Schneeberger AG, Kösters MC, Steens W. Comparison of the subjective elbow value and the Mayo Elbow Performance Score. *J Shoulder Elbow Surg*. 2014;23:308-12.
 22. Cusick MC, Bonnaig NS, Azar FM, Mauck BM, Smith RA, Throckmorton TW. Accuracy and reliability of the Mayo Elbow Performance Score. *J Hand Surg Am*. 2014;39(6):1146-50.
 23. An Z, He x, Zeng B. A comparative study on open reduction and plating osteosynthesis and minimal invasive plating osteosynthesis in treating mid-distal humeral shaft fractures. *Zhongguo Xiu Fu Chong Jian Wai Ke Za Zhi*. 2009;23(1):41-4.
 24. Lee T, Yoon J. Newly designed minimally invasive plating of a humerus shaft fracture; a different introduction of the plate. *Int Orthop*. 2016;40(12):2597-602.
 25. Gallucci G, Vujovich A, Boretto J, Alfie V, Donndorff A, Carli P. Técnica Mínimamente invasiva por vía posterior para el tratamiento de fracturas diafisarias de húmero. *Rev Asoc Argent Ortop Traumatol*. 2013;78:64-73.
 26. Limthongthang R, Jupiter JB. Distal Humerus Fractures. 2013;23:178-187
 27. Spitzer AB, Davidovitch RI, Egol KA. Use of a “hybrid” locking plate for complex metaphyseal fractures and nonunions about the humerus. *Injury*. 2009;40(3):240-44.
 28. Meloy GM, Mormino MA, Siska PA, Tarkin IS. A paradigm shift in the surgical reconstruction of extra-articular distal humeral fractures: Single-column plating. *Injury*. 2013;44(11):1620-624.
 29. Illical EM, Farrell DJ, Siska PA, Evans AR, Gruen GS, Tarkin IS. Comparison of outcomes after triceps split versus sparing surgery for extra-articular distal humerus fractures. *Injury*. 2014;45(10):1545-548.
 30. Lawrence TM, Ahmadi S, Morrey BF, Sánchez-Soletto J. Wound complications after distal humerus fracture fixation: incidence, risk factors, and outcome. *J Shoulder Elbow Surg*. 2014;23(2):258-64.
 31. Lian K, Wang L, Lin D, Chen Z. Minimally invasive plating osteosynthesis for mid-distal third humeral shaft fractures. *Orthopedics*. 2013;36(8):e1025-32.
 32. Rupenian PR. Osteosíntesis mínimamente invasiva con placa en fracturas diafisarias de húmero. *Ver Asoc Argent Ortop Traumatol*. 2013;78:53-63
 33. Zogbi DR, Terrivel AM, Mouraria GG, Mongon MLD, Kikuta FK, Filho ZA. Fratura distal da diáfise umeral: Técnica MIPO com visualização do nervo radial. *Acta Ortop Bras*. 2014;22(6):300-33.
 34. The B, Reininga IH, El Moumni M, Eygendaal D. Elbow-specific clinical rating systems: extent of established validity, reliability, and responsiveness. *J Shoulder Elbow Surg*. 2013;22(10):1380-94.
 35. Kharbanda Y, Tanwar YS, Srivastava V, Birla V, Rajput A, Pandit R. Retrospective analysis of extra-articular distal humerus shaft fractures treated with the use of pre-contoured lateral column metaphyseal LCP by triceps-sparing posterolateral approach. *Strategies trauma Limb Reconstr*. 2017;12(1):1-9.
 36. Yang Q, Wang F, Wang Q, Gao W, Huang J, Wu J, Chen H. Surgical treatment of adult extra-articular distal humeral diaphyseal fractures using an oblique metaphyseal locking compression plate via a posterior approach. *Med Princ Pract*. 2012;21(1):40-5.
 37. Tejwani NC, Murthy A, Park J, McLaurin TM, Egol KA, Kummer FJ. Fixation of extra-articular distal humerus fractures using one locking plate versus two reconstruction plates: a laboratory study. *J Trauma*. 2009;66(3):795-99.
 38. Santos RR, Rahal SC, Neto CM, Ribeiro CR, Sousa EAC, Foschini CR, Agostinho FS,

- Mesquita LR. Biomechanical analysis of locking reconstruction plate using mono or bicortical screws. *Mat Research*. 2016;19(3):588-93.
39. Orfale AG, Araújo PMP, Ferraz MB, Natour J. Translation into Brazilian Portuguese, cultural adaptation and evaluation of the reliability of the Disabilities of the Arm, Shoulder and Hand Questionnaire. *Braz J Med Biol Res*. 2005; 38:293-302.

CONFLICTS OF INTERESTS

The authors declare no conflicts of interests.

CORRESPONDING AUTHOR

Luis Guilherme Rosifini Alves Rezende

Department of Orthopaedics and Anesthesiology of the Hospital of Clinics of Ribeirao Preto Medical School of the University of São Paulo.
Av. Bandeirantes, 3900, 11th Floor, Ribeirao Preto, Sao Paulo, Brazil, 14900-090.
E-mail: lgrezende@usp.br

Received 19/01/2022

Accepted 28/03/2022