

Rare Nodular Lesion on Gingiva - Peripheral Odontogenic Fibroma

Lesão Rara Afetando a Gengiva - Fibroma Odontogenico Periférico

Lesión Rara que Afecta la Encía - Fibroma Odontogénico Periférico

Camila Lopes **CARDOSO**

Department of Oral and Maxillofacial Surgery, Unisagrado, 17011-160 Bauru - SP, Brazil
<https://orcid.org/0000-0001-9545-6809>

Leticia Maria Pereira **TEIXEIRA**

Department of Oral and Maxillofacial Surgery, Unisagrado, 17011-160 Bauru - SP, Brazil
<https://orcid.org/0000-0002-5379-1171>

Gabriel Lúcio Calazans **DUARTE**

Department of Oral and Maxillofacial Surgery, University of São Paulo (USP), 14040-904 Ribeirão Preto - SP, Brazil
<https://orcid.org/0000-0002-0257-1494>

Heitor Albergoni **SILVEIRA**

Department of Diagnosis and Surgery, Araraquara Dental School, São Paulo State University (UNESP), 14801-385 Araraquara - SP, Brazil
<https://orcid.org/0000-0002-6724-3504>

Beethoven Esteveao **COSTA**

Department of Oral and Maxillofacial Surgery, HRAC, University of São Paulo (USP), 17012-901 Bauru - SP, Brazil
<https://orcid.org/0000-0002-4274-2883>

Silas Antonio Juvencio de **FREITAS FILHO**

Department of Surgery, Stomatology, Pathology and Radiology, Bauru School of Dentistry, University of São Paulo (USP),
17012-901 Bauru - SP, Brazil
<https://orcid.org/0000-0002-6478-7477>

Alberto **CONSOLARO**

Department of Surgery, Stomatology, Pathology and Radiology, Bauru School of Dentistry, University of São Paulo (USP),
17012-901 Bauru - SP, Brazil
<https://orcid.org/0000-0002-5902-5646>

Paulo Domingos **RIBEIRO JÚNIOR**

Department of Oral and Maxillofacial Surgery, Unisagrado, 17011-160 Bauru - SP, Brazil
<https://orcid.org/0000-0003-0956-2395>

Abstract

Peripheral odontogenic fibroma (POF) is a rare lesion, the extraosseous counterpart of the odontogenic fibroma, an odontogenic tumor of ectomesenchymal origin. Clinically it resembles as the reactional processes and has slow growth. The purpose of the study is to present a clinical case of posterior maxillary POF mimicking inflammatory periodontal disease in a 42-year-old woman who, after complete surgical excision, is followed up every six months without recurrence of the lesion. POF is a lesion characterized by fibroblast proliferation containing portions of apparently inactive odontogenic epithelium. The surgical treatment, when well performed, presents a very favorable prognosis, with a rare chance of relapse. It is important to emphasize that all the gingival lesions should be submitted to the anatomopathological examination, and the radiographic examination of the region is fundamental to evaluate the extent of the lesion.

Descriptors: Odontogenic Tumors; Mouth Neoplasms; Peripheral Odontogenic Fibroma.

Resumo

O fibroma odontogênico periférico (FOP) é uma lesão rara, a contraparte extraóssea do fibroma odontogênico, um tumor odontogênico de origem ectomesenquimal. Clinicamente se assemelha aos processos reacionais e tem crescimento lento. O objetivo do estudo é apresentar um caso clínico de FOP maxilar posterior mimetizando doença periodontal inflamatória em uma mulher de 42 anos que, após excisão cirúrgica completa, é acompanhada semestralmente sem recorrência da lesão. O FOP é uma lesão caracterizada pela proliferação de fibroblastos contendo porções de epitélio odontogênico aparentemente inativo. O tratamento cirúrgico, quando bem realizado, apresenta prognóstico bastante favorável, com rara chance de recidiva. É importante ressaltar que todas as lesões gengivais devem ser submetidas ao exame anatomopatológico, e o exame radiográfico da região é fundamental para avaliar a extensão da lesão.

Descritores: Tumores Odontogênicos; Neoplasias Buciais; Fibroma Odontogênico Periférico.

Resumen

El fibroma odontogénico periférico (FOP) es una lesión rara, la contraparte extraósea del fibroma odontogénico, un tumor odontogénico de origen ectomesenquimatoso. Clinicamente se asemeja a los procesos reaccionales y tiene un crecimiento lento. El objetivo del estudio es presentar un caso clínico de FOP maxilar posterior que simula enfermedad periodontal inflamatoria en una mujer de 42 años a la que, tras extirpación quirúrgica completa, se le hace seguimiento cada seis meses sin recurrencia de la lesión. La POF es una lesión caracterizada por la proliferación de fibroblastos que contiene porciones de epitelio odontogénico aparentemente inactivo. En la literatura, se ha informado poco, más comúnmente en un formato de informe de caso clínico. El tratamiento quirúrgico, bien realizado, presenta un pronóstico muy favorable, con una rara posibilidad de recaída. Es importante resaltar que todas las lesiones gingivales deben ser sometidas al examen anatomopatológico, y el examen radiográfico de la región es fundamental para evaluar la extensión de la lesión.

Descriptores: Tumores Odontogénicos; Neoplasias Buciales; Fibroma Odontogénico Periférico.

INTRODUCTION

Odontogenic Fibroma (OF) is a benign tumor of odontogenic origin with ectomesenchymal components: mature fibrous connective tissue and inactive-looking odontogenic epithelium, with or without areas of calcification^{1,2}. The OF presents its extraosseous version denominated peripheral

odontogenic fibroma POF¹⁻⁴.

POF is a rare tumor and occurs mainly in the vestibular gingiva, with a higher incidence in the papilla with focal growth^{3,4}. Clinically, the clinical aspect of POF is similar to reactional lesions or non-neoplastic proliferative processes, such as peripheral ossifying fibroma, giant cell peripheral lesion, pyogenic

granuloma, hence the importance of sending any lesion for anatomopathological analysis^{1,2,5,6}.

The treatment of POF consists of its complete removal, and, when well performed, its prognosis is very favorable, with a rare chance of recurrence¹⁻⁴. This article aimed to report a rare case of peripheral odontogenic fibroma mimicking inflammatory periodontal disease in a 42-year-old woman and to discuss relevant topics about the diagnosis and treatment of this lesion.

CLINICAL CASE

A 42-year-old woman attended our Service of Stomatology complaining of a mass in the gingiva. Physical examination revealed a pedunculated nodular lesion involving the alveolar ridge in the gingival area in the 27 region, measuring approximately 2,5 x 2,0 cm, asymptomatic, resilient to palpation, with two years of evolution, without definite cause (Figure 1).

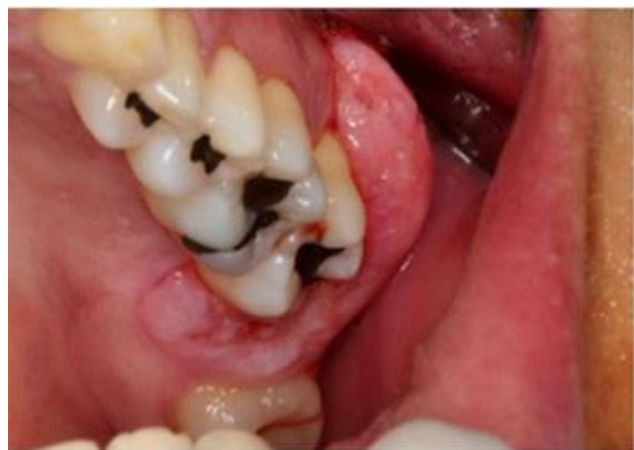

Figure 1. Nodular lesion in the alveolar ridge in the 27 region.

In patient medical history, there was nothing noteworthy. On panoramic radiography, teeth 27 and 28 revealed advanced periodontal impairment (Figure 2). The presumptive diagnosis was of an inflammatory periodontal disease or a non-neoplastic proliferative process such as pyogenic granuloma, giant cell peripheral lesion and peripheral ossifying fibroma.

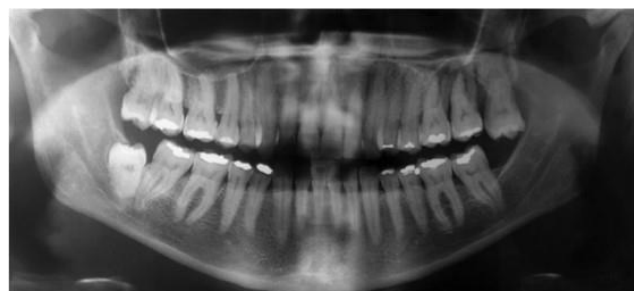


Figure 2. Panoramic radiography revealing the teeth 27 and 28 with advanced periodontal disease.

The patient underwent an incisional biopsy, and the initial diagnosis was compatible with chronic inflammatory periodontal disease. Considering the clinical, radiographic and microscopic aspects, the treatment was the excision of the lesion and exodontia of the teeth 27 and 28. The lesion was completely removed and sent for microscopic examination (Figure 3).

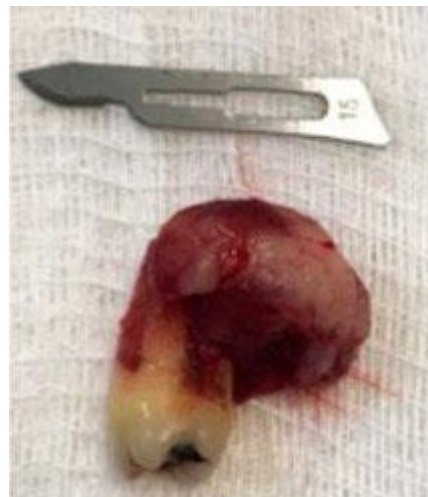

Figure 3. Surgical specimen of the lesion after total excision.

The histopathological analysis the surgical specimen revealed gingival mucosa with parakeratinized hyperplastic squamous stratified epithelium, submucosa with fascicular arrangements of young fibroblast cells in dense collagen fiber bundles and some disorganized areas, few islands of apparently inactive odontogenic epithelium, foci of mineralized cementoid-like material, besides of mononuclear inflammatory infiltrate (Figure 4). The final diagnosis was Peripheral odontogenic fibroma (POF). After two years of follow-up, there was no sign of clinical and radiographic recurrence.

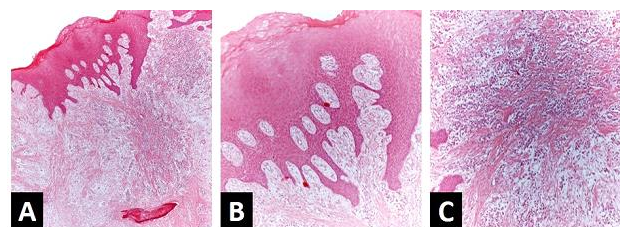


Figure 4. Microscopic features (H and E staining). Gingival mucosa with parakeratinized hyperplastic squamous stratified epithelium, submucosa with fascicular arrangements of young fibroblast cells in dense collagen fiber bundles and some disorganized areas, foci of mineralized cementoid-like material and mononuclear inflammatory infiltrate (A, 50x). Parakeratinized hyperplastic squamous stratified epithelium, submucosa with fascicular arrangements of young fibroblast cells in dense collagen fiber bundles and some disorganized areas and few islands of odontogenic epithelium (B, 100x). Presence of fascicular arrangements of young fibroblast cells in dense collagen fiber bundles and some disorganized, few islands of odontogenic epithelium, besides of mononuclear inflammatory infiltrate (C, 200x).

DISCUSSION

Peripheral odontogenic tumors are rare lesions, and the odontogenic fibroma is considered the most frequent tumor presenting its peripheral version, followed by ameloblastoma and calcifying cystic odontogenic tumor^{3,4}. Recent epidemiological studies on odontogenic tumors in the Brazilian population showed that odontogenic fibroma represents only 1.6% to 2.1% of all these lesions^{7,8}.

A review of the English-language literature using the Pubmed database, searching by term "peripheral odontogenic fibroma" was performed and 145 articles were found from 1958 to 2020, and restricting this term to the title, only 47 studies were found. To date, the series of cases with the highest number of PFO has been presented by Ritwik et al.¹ with 151 cases, comprising 23% of all odontogenic tumors in the Service. A discrepancy in the frequency of this tumor can be seen between studies from different countries.

The clinical aspect of POF is a nodular or pedunculated nodular lesion, asymptomatic, with slow and persistent growth, resembling non-neoplastic proliferative processes such as peripheral ossifying fibrosis, traumatic fibroma, pyogenic granuloma, even peripheral giant cell lesion. The overlap of clinical characteristics of gingival lesions, as reported in our case, and of challenging clinical diagnosis, was also shown in the study by Bharathi et al.⁵ Regarding the pathogenesis of this tumor, it is believed that the interaction between odontogenic epithelium and mesenchymal components, as occurs in odontogenesis, is seen here, but unregulated^{1,2,5,6}.

In the present case, an incisional biopsy was initially chosen, since the involved teeth had significant periodontal involvement and, for adequate definitive treatment, the diagnosis would be important. However, the result of the initial biopsy was non-specific, but considering the exclusion of other malignant lesions, the planning was based considering the lesion as a reactional condition.

POF presents a slight tendency to the female gender, as in the present case, and its age range can vary from 5 to 65 years⁹. PFO affects the mandible more than the maxilla, with a predominance of the anterior region, rarely causing movement of the adjacent teeth¹. In the present case, the lesion presented a history of two years of evolution, asymptomatic, in the

posterior region of the maxilla and causing a slight displacement of the tooth 27 towards the outside of the alveolar ridge.

In addition to the basic histopathological characteristics, the professional must consider the odontogenic fibroma variants, such as ossifying variant, with giant cell lesions and amyloid-like protein deposition¹⁰.

Regarding the treatment, the best choice for POF, the appropriate treatment is its complete excision with curettage of the adjacent areas. In the present case, the two teeth close to the lesion were extracted as a result of the advanced periodontal impairment that they presented. According to Bharathi et al.⁵ understanding the clinical and microscopic characteristics, in addition to the biological behavior of gingival lesions, is useful to provide the appropriate treatment.

Considering some cases of recurrence reported in the literature^{9,11}, clinical and radiographic monitoring is essential. A case of a POF that presented two recurrences, one of them being of central form, emphasizes the importance of the initial radiographic investigation¹¹. Sreeja et al.⁶ believe that recurrence may be associated with the presence of basal cell budding.

CONCLUSION

In summary, all gingival lesions should be submitted to radiographic examination to evaluate the extent of the lesion and histopathological analysis to establish an accurate diagnosis. In addition, monitoring of all patients should be done every six months.

REFERENCES

1. Ritwik P, Brannon RB. Peripheral odontogenic fibroma: a clinicopathologic study of 151 cases and review of the literature with special emphasis on recurrence. *Oral Surg Oral Med Oral Pathol Oral Radiol Endod.* 2010;110(3):357-363.
2. Khot K, Deshmane S, Bagri-Manjrekar K, Khot P. Peripheral Odontogenic Fibroma: A Rare Tumor mimicking a Gingival Reactive Lesion. *Int J Clin Pediatr Dent.* 2017;10(1):103-106.
3. Armas JM, Hunter KD, Jenkins WM. Odontogenic fibroma: An unusual presentation. *J Oral Maxillofac Pathol* 2008;12:68-71.
4. Baiju CS, Rohatgi S. Peripheral odontogenic fibroma: A case report and review. *J Indian Soc Periodontol.* 2011;15(3):273-275.
5. Bharathi DR, Sangamithra S, Arun KV, Kumar TS. Isolated lesions of gingiva: A case series and review. *Contemp Clin Dent.* 2016;7(2):246-249.

6. Sreeja C, Vezhavendan N, Shabana F, Vijayalakshmi D, Devi M, Arunakiry N. Recurrent peripheral odontogenic fibroma associated with basal cell budding. *J Pharm Bioallied Sci.* 2014;6(Suppl 1):S204-S207.
7. de Medeiros WK, da Silva LP, Santos PP, Pinto LP, de Souza LB. Clinicopathological analysis of odontogenic tumors over 22 years period: Experience of a single center in northeastern Brazil. *Med Oral Patol Oral Cir Bucal.* 2018;23(6):e664-e671.
8. da Silva LP, Serpa MS, Tenório JR, do Nascimento GJ, de Souza-Andrade ES, Veras-Sobral AP. Retrospective study of 289 odontogenic tumors in a Brazilian population. *Med Oral Patol Oral Cir Bucal.* 2016;21(3):e271-e275.
9. Daley TD, Wysocki GP. Peripheral odontogenic fibroma. *Oral Surg Oral Med Oral Pathol.* 1994;78(3):329-336.
10. Amaral MB, Souto GR, Horta MC, Gomez RS, Mesquita RA. Ossifying odontogenic fibroma: A rare case report. *J Clin Exp Dent.* 2014;6(5):e588-e591.
11. Reddy SV, Medikonda SK, Konda A, Natta S. A rare benign odontogenic neoplasm: peripheral odontogenic fibroma. *BMJ Case Rep.* 2014;2014:bcr2013201065.

CONFLICTS OF INTERESTS

The authors declare no conflicts of interests.

CORRESPONDING AUTHOR

Camila Lopes Cardoso

Department of Oral Surgery, Unisagrado,
Bauru - SP, Brazil

Email: cardoso_lopes@yahoo.com.br

Received 04/05/2022

Accepted 28/07/2022